

PATIENT

Finnick Mello

SPECIES

Canine

BREED

Chihuahua Mix

SEX

MN

AGE

5 y

WEIGHT

14 lb

INTERPRETED BY

Keith Blass, DVM, MS,
DACVIM (Cardiology)

IMAGING PERFORMED BY

Karen Ebersole, DVM,
DABVP

HOSPITAL NAME

Scanvet

REFERRING VET

Dr. Berdahl

INVOICE

DATE

12/10/25

PRESENTING CLINICAL SIGNS

Pre-anesthetic evaluation (dental). No murmur. Seizures/epilepsy.

ECHOCARDIOGRAPHIC FINDINGS

2D, M-mode, and Doppler study.

Left atrial size is normal. The mitral valve is normal. Left ventricular dimensions are normal. Left ventricular systolic function is normal. The aorta and aortic valve are normal. Right atrial and right ventricular dimensions are normal. The tricuspid valve appears normal, though trace tricuspid regurgitation is present. The pulmonary artery and pulmonic valve are normal. No shunting lesions are visualized. No heartworms are visualized. No pericardial effusion or cardiac masses are seen.

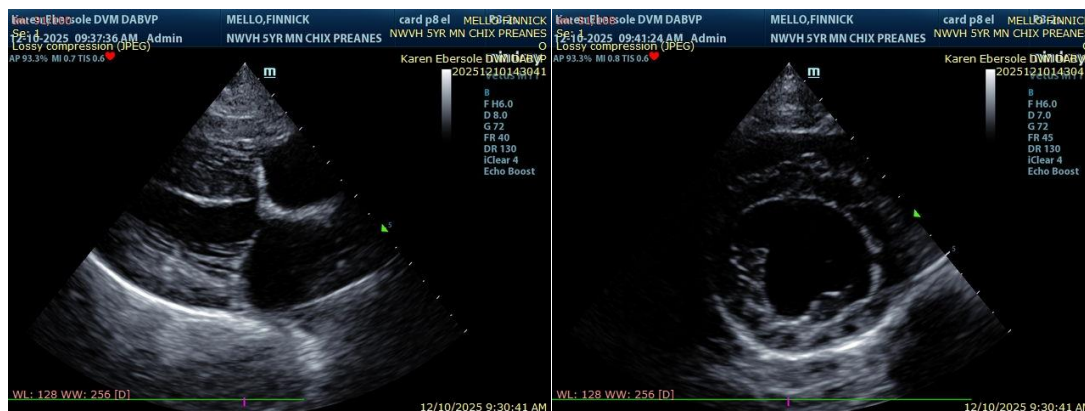
ASSESSMENT/RECOMMENDATIONS

Normal echocardiogram

This examination demonstrates no evidence of structural heart disease, as trace tricuspid regurgitation can be considered a normal physiologic variant. As such, no contraindication to general anesthesia is appreciated in this exam.

No therapy is recommended based on this exam.

A recheck echocardiogram is recommended if new physical exam and/or clinical abnormalities suggestive of the presence of cardiac dysfunction develop.



The information and recommendations provided are based on the images presented by the referring veterinarian/sonographer. No evaluation can be communicated regarding pathology that was not visible in the image/video clips provided.

Thank you for this referral. If the clinical or image interpretation does not parallel your findings or if I



PATIENT

Finnick Mello

SPECIES

Canine

BREED

Chihuahua Mix

SEX

MN

AGE

5 y

WEIGHT

14 lb

INTERPRETED BY

Keith Blass, DVM, MS,
DACVIM (Cardiology)

**IMAGING
PERFORMED BY**

Karen Ebersole, DVM,
DABVP

HOSPITAL NAME

Scanvet

REFERRING VET

Dr. Berdahl

INVOICE

DATE

12/10/25

can be of any further assistance please contact me.

Keith Blass, DVM, MS, DACVIM (Cardiology)

info@SonoPath.com